

## Review

# International Society of Urological Pathology (ISUP) Consensus Conference on Handling and Staging of Radical Prostatectomy Specimens. Working group 4: seminal vesicles and lymph nodes

Daniel M Berney<sup>1</sup>, Thomas M Wheeler<sup>2</sup>, David J Grignon<sup>3</sup>, Jonathan I Epstein<sup>4</sup>, David F Griffiths<sup>5</sup>, Peter A Humphrey<sup>6</sup>, Theo van der Kwast<sup>7</sup>, Rodolfo Montironi<sup>8</sup>, Brett Delahunt<sup>9</sup>, Lars Egevad<sup>10</sup>, John R Srigley<sup>11</sup> and the ISUP Prostate Cancer Group\*

<sup>1</sup>Department of Molecular Oncology and Imaging, St Bartholomew's Hospital Queen Mary University of London, London, UK; <sup>2</sup>Department of Pathology, Baylor College of Medicine, Houston, TX, USA; <sup>3</sup>Clarian Pathology Laboratory, Indiana University School of Medicine, Indianapolis, IN, USA; <sup>4</sup>Department of Pathology, Johns Hopkins Hospital, Baltimore, MD, USA; <sup>5</sup>Department of Pathology, Cardiff University School of Medicine, University Hospital of Wales, Cardiff, UK; <sup>6</sup>Department of Pathology and Immunology, Washington University School of Medicine, St Louis, MO, USA; <sup>7</sup>Department of Pathology, University Health Network and University of Toronto, Toronto, ON, Canada; <sup>8</sup>IFCAP, Section of Pathological Anatomy, Polytechnic University of the Marche Region, School of Medicine, United Hospitals, Ancona, Italy; <sup>9</sup>Department of Pathology and Molecular Medicine, Wellington School of Medicine and Health Sciences, University of Otago, Wellington, New Zealand; <sup>10</sup>Department of Oncology-Pathology, Karolinska Institutet, Stockholm, Sweden and <sup>11</sup>Department of Pathology and Molecular Medicine, McMaster University, Hamilton, ON, Canada

**The 2009 International Society of Urological Pathology Consensus Conference in Boston made recommendations regarding the standardization of pathology reporting of radical prostatectomy specimens. Issues relating to the infiltration of tumor into the seminal vesicles and regional lymph nodes were coordinated by working group 4. There was a consensus that complete blocking of the seminal vesicles was not necessary, although sampling of the junction of the seminal vesicles and prostate was mandatory. There was consensus that sampling of the vas deferens margins was not obligatory. There was also consensus that muscular wall invasion of the extraprostatic seminal vesicle only should be regarded as seminal vesicle invasion. Categorization into types of seminal vesicle spread was agreed by consensus to be not necessary. For examination of lymph nodes, there was consensus that special techniques such as frozen sectioning were of use only in high-risk cases. There was no consensus on the optimal sampling method for pelvic lymph node dissection specimens, although there was consensus that all lymph nodes should be completely blocked as a minimum. There was also a consensus that a count of the number of lymph nodes harvested should be attempted. In view of recent evidence, there was consensus that the diameter of the largest lymph node metastasis should be measured. These consensus decisions will hopefully clarify the difficult areas of**

Correspondence: Dr DM Berney, FRCPath, Barts and The Royal London Hospitals, 80 Newark Street, London, E1 2 ES, UK.  
E-mail: D.Berney@bartsandthelondon.nhs.uk

\*See Appendix.

Received 25 October 2009; revised 22 July 2010; accepted 28 July 2010; published online 3 September 2010

**pathological assessment in radical prostatectomy evaluation and improve the concordance of research series to allow more accurate assessment of patient prognosis.**

*Modern Pathology* advance online publication, 3 September 2010; doi:10.1038/modpathol.2010.160

**Keywords:** lymph node; prostate adenocarcinoma; radical prostatectomy; seminal vesicle; tumor staging

The identification of seminal vesicle invasion and lymph node metastasis have an important role in determining a patient's prognosis after radical prostatectomy, and may guide appropriate subsequent therapy by use of a number of predictive models.<sup>1–4</sup> However, in spite of the large and increasing numbers of radical prostatectomies performed in developed countries in the last 20 years, there is considerable variation in the pathological handling of the seminal vesicles in radical prostatectomy specimens and of associated lymph nodes. Subtle differences in the guidance issued, or in omissions of detail, may lead to significant reporting differences.<sup>5–9</sup> The consequences of this are considerable, leading to great difficulty in comparing results from one institution to another (or even one pathologist to another) and recent surveys have exemplified these problems.<sup>10</sup> From the patient's perspective, the risks of recurrence may be given, which are misleading, and potentially inappropriate therapy instituted. The International Society of Urological Pathology therefore considered both these areas of contention as part of a consensus conference.

### **International Society of Urological Pathology Survey and Consensus Conference**

In order to identify the methods and practices most commonly employed by urological pathologists worldwide, a web-based survey on handling and reporting of radical prostatectomy specimens was distributed to 255 members of the International Society of Urological Pathology.

The International Society of Urological Pathology survey was followed up with a consensus conference held in conjunction with the 2009 Annual Scientific Meeting of the United States and Canadian Academy of Pathology held in Boston, Massachusetts. The aim was to obtain consensus relating to the handling, staging and reporting of radical prostatectomy specimens. Those who completed the electronic survey were invited to attend the consensus conference that was held on 8 March. The detailed process related to the survey and consensus meeting are reported in an introductory paper.<sup>11</sup>

Representatives from five working groups appointed to coordinate the consensus process presented background information and results from detailed literature reviews to the meeting. The survey results were then discussed with the objective of achieving agreement on controversial issues. Following this, a ballot was taken on a series of questions that were designed to address these controversial issues and an achieve-

ment of 65% agreement on voting was considered to be consensus. With a few exceptions, there was agreement between the survey results and the consensus conference results. The results of the individual working group reports related to specimen handling, T2 substaging, extraprostatic extension, seminal vesicle and lymph node involvement and margin status are reported separately.<sup>12–15</sup>

Many recommendations of this consensus conference have already been incorporated into international guidelines, including the recent College of American Pathologists protocol and checklist for reporting adenocarcinoma of the prostate and the structured reporting protocol for prostatic carcinoma from the Royal College of Pathologists of Australasia.<sup>16,17</sup>

### **Seminal vesicle invasion**

#### **Macroscopic Assessment**

Seminal vesicle invasion by prostatic adenocarcinoma (pT3b) has generally been shown to be a predictor of poor prognosis after radical prostatectomy,<sup>18–21</sup> and is commonly associated with other forms of extraprostatic extension such as infiltration into surrounding adipose tissue. Despite this, the literature relating to seminal vesicle infiltration by tumor was greatly distorted by differences in how the seminal vesicles are sampled and assessed. This issue was considered in a comprehensive literature review<sup>22</sup> that revealed large differences in major series, in both the percentages of cases with seminal vesicle invasion and in the 5-year recurrence-free survival that ranged from 5 to 60%.<sup>19–21,23–27</sup> The main conclusions from the literature search were that conformity to one definition and a uniform approach to seminal vesicle invasion is essential for the analysis and comparison of future radical prostatectomy series, in order to derive staging information that provides meaningful data for survival analysis and prognostic tables.

#### **Survey and Consensus Conference Results**

There was no survey consensus as to the most appropriate method for dissection of the seminal vesicles (Table 1). Of survey respondents, 45% reported that they sliced seminal vesicles transversely, whereas 33% sliced longitudinally and 18% employed a combination of these techniques. There were similar degrees of disagreement as to whether seminal vesicles should be submitted completely,

**Table 1** Comparison of survey results with consensus conference results

|                                           | <i>Survey results</i>    |                 | <i>Consensus conference results</i> |             |              |
|-------------------------------------------|--------------------------|-----------------|-------------------------------------|-------------|--------------|
|                                           | <i>Number responding</i> | <i>Survey %</i> | <i>Number responding</i>            | <i>CC %</i> |              |
| SV sampling                               | 157                      |                 | 109                                 |             |              |
| 'Complete'                                |                          | 38              |                                     | <b>13</b>   | Consensus    |
| 'Selective'                               |                          | 52              |                                     | <b>87</b>   |              |
| 'It depends'                              |                          | 10              |                                     |             |              |
| Direction of SV sampling                  | <b>157</b>               |                 | NA                                  | <b>NA</b>   |              |
| Transverse                                |                          | 45              |                                     |             |              |
| Longitudinal                              |                          | 33              |                                     |             |              |
| Combination                               |                          | 18              |                                     |             |              |
| Junction of SV and prostate taken         | 156                      | <b>97</b>       | NA                                  | NA          | Consensus    |
| Vas margin sampling not obligatory        | 157                      | 54              | 109                                 | <b>78</b>   | Consensus    |
| SVI defined as muscular wall invasion     | 157                      | <b>80</b>       | NA                                  | NA          | Consensus    |
| Only extraprostatic SVI                   | 156                      | 47              | 107                                 | <b>70</b>   | Consensus    |
| Ejaculatory duct invasion not pT3b        | 92                       | <b>89</b>       | NA                                  | NA          | Consensus    |
| Method of SVI not recorded                | 154                      | <b>80</b>       | NA                                  | NA          | Consensus    |
| Vascular invasion of SV only is pT3b      | 151                      | 55              | 106                                 | 56          | No consensus |
| All nodal tissues (not fat) submitted     | 157                      | 68              | 109                                 | 59          | No consensus |
| % Cases with lymph nodes                  | 156                      |                 | NA                                  | NA          | No consensus |
| 0%                                        |                          | 1               |                                     |             |              |
| 1–10%                                     |                          | 26              |                                     |             |              |
| 11–50%                                    |                          | 31              |                                     |             |              |
| 50–90%                                    |                          | 21              |                                     |             |              |
| >90%                                      |                          | 21              |                                     |             |              |
| Always count lymph nodes                  | 157                      | <b>95</b>       | NA                                  | NA          | Consensus    |
| Sentinel node not submitted               | 157                      | <b>97</b>       | NA                                  | NA          | Consensus    |
| Frozen section submitted                  | 157                      |                 | NA                                  | NA          |              |
| Never                                     |                          | 22              |                                     |             |              |
| 1–10%                                     |                          | 57              |                                     |             |              |
| 11–50%                                    |                          | 15              |                                     |             |              |
| 51–90%                                    |                          | 3               |                                     |             |              |
| >90%                                      |                          | 3               |                                     |             |              |
| Measure largest metastasis                | 155                      | 47              | 108                                 | <b>81</b>   | Consensus    |
| Presence of extra nodal invasion recorded | 156                      | <b>88</b>       | NA                                  | NA          | Consensus    |

NA, not asked, so does not apply; SV, seminal vesicles; SVI, seminal vesicle invasion.

Bold = consensus.

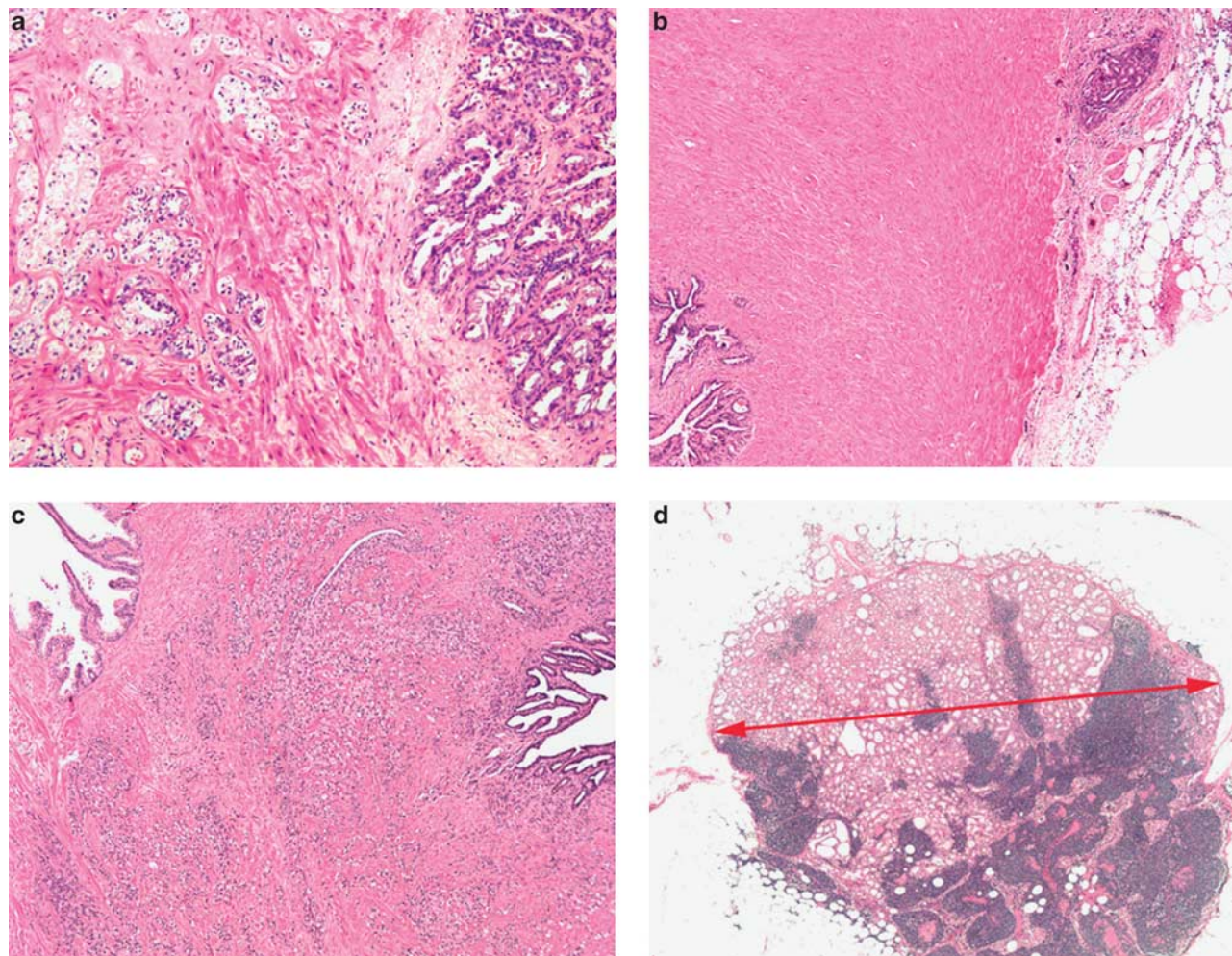
with 38% practicing complete embedding whereas 52% only partially embedding the seminal vesicles, and the remainder completely embedding only in some cases. The methods of complete sampling were similarly highly variable among the respondents to the survey, although there was general agreement that sections taken from the junction of the prostate and the seminal vesicle should be mandatory. It was noted that the tip or mid portion of the seminal vesicle was sampled by a minority and the conference achieved consensus by agreeing that complete embedding of the seminal vesicles should not be mandatory (Table 1).

Based on the survey results, it is recommended that the junction of the seminal vesicle and the prostate should always be assessed for contiguous spread of tumor. This should be considered the minimum necessary to adequately sample the seminal vesicles. Remaining blocks to assess the rarer situation of noncontiguous spread could be taken if desired or if areas macroscopically suspicious for invasion are identified.

Another area of controversy is the necessity of sampling the vas deferens margins. These were sampled by some respondents to the survey with the rationale that these represent surgical margins. We are unaware of any study that addresses this issue specifically and the separation of this feature from seminal vesicle invasion. It would seem logical that positivity at this margin would be associated with contiguous invasion of the seminal vesicles, but sampling here appears to be unreported in most major series. In the survey, there was a significant split with 46% of pathologists reporting sampling the vas deferens margin; however, at the consensus conference, there was consensus that this should not be mandatory.

### Seminal Vesicle Microscopic Assessment

Seminal vesicle invasion is defined by some groups as tumor infiltration of the muscular wall (Figure 1a),<sup>28</sup> whereas other older definitions



**Figure 1** (a) Extraprostatic seminal vesicle invasion (pT3b). Tumor is seen infiltrating the muscle wall (left). The seminal vesicle epithelium is not infiltrated by tumor (right). (b) Extraprostatic seminal vesicle invasion with small cancer focus growing from outside (right) in the fibroadipose tissue. Seminal vesicle glands are seen in lower left corner. (c) Prostate cancer invading the intraprostatic part of the seminal vesicle (pT3a). Central zone of the prostate is seen to the left. Cancer is seen infiltrating the intraprostatic part of the seminal vesicle to the right. (d) Lymph node metastasis with arrow indicating how maximum diameter should be measured.

have included invasion of the periseminal vesicle adipose tissue (Figure 1b);<sup>29</sup> thus, different series assess differing microscopic criteria. Furthermore, many studies do not specify which assessment method was used, and hence these data are difficult to analyze. If tumor infiltration of the adipose and connective tissue surrounding the seminal vesicle is to be defined as seminal vesicle invasion, then any distinction from extraprostatic invasion outside the seminal vesicles will be difficult and may have to be based on arbitrary measures. There was a consensus at 80% in the survey that only muscularis invasion constitutes seminal vesicle invasion, although a substantial minority would also accept peri-adipose tissue invasion around the seminal vesicle as indicative of tumor infiltration. There are large problems with defining exactly how near the adipose tissue invasion has to be to the seminal vesicles, which further complicates the distinction between extraprostatic extension and

seminal vesicle invasion. The inclusion of invasion of adipose tissue that surrounds the seminal vesicles or invasion in the invaginated space as a feature of seminal vesicle invasion raises further problems of definition relating to how near to the seminal vesicles does the cancer need to be. On current evidence this would have to be an arbitrary distance, chosen with little rationale. For these reasons, muscularis invasion is recommended as the definition of invasion of the seminal vesicles.

A second more contentious problem is the distinction between intraprostatic and extraprostatic seminal vesicle invasion (Figure 1c). This problem was presented in the survey as a key issue of controversy. The seminal vesicles are not purely extraprostatic organs, but extend and connect with the prostate ejaculatory duct. As ejaculatory duct epithelium is difficult to distinguish from the seminal vesicles, and is present within the anatomical bounds of the prostate, differences in

definition will lead to variations in the number of cases considered to have seminal vesicle invasion.

If intraprostatic seminal vesicle invasion is considered pT3b, then its differentiation from ejaculatory duct invasion status is of importance. This is not an issue if only extraprostatic seminal vesicle invasion is considered as pT3b. One interesting study that examined tumors showed invasion only of the intraprostatic portion of the seminal vesicle and ejaculatory duct, and showed that the survival rate was considerably more favorable than for those with extraprostatic seminal vesicle invasion.<sup>30</sup>

Prostatic carcinoma can invade the extraprostatic seminal vesicles by spreading along the ejaculatory duct (type 1), by direct invasion at the base of the prostate or by extending into peri-seminal vesicle soft tissue and then into the wall of the seminal vesicle (type 2) or, rarely, via discontinuous metastases (type 3).<sup>28,31</sup> Although these routes of infiltration are classified separately, it has been noted that types 1 and 2 invasion frequently occur together. The distinction of the main types of extraprostatic seminal vesicle invasion and their prognostic significance also has a scanty literature.<sup>32</sup> The major findings appear to be that the discontinuous form is much rarer than direct spread. Although this earlier study suggested that those with discontinuous seminal vesicle invasion have a better outcome, this did not hold up on multivariate analysis when lymph node metastasis was also considered: unsurprisingly, considering their rarity. The risk of relapse has also been stratified by the amount of seminal vesicle involvement, but from the lack of specific comments from the survey, this is not yet routinely performed.<sup>33,34</sup>

In the survey, a majority either did not offer an opinion or did not consider ejaculatory duct invasion to be extraprostatic extension. Additional to this, 89% of respondents did not consider ejaculatory duct invasion to be a feature of pT3b staging category (Table 1). As there is little evidence based on this issue, a satisfactory outcome would be the achievement of uniformity of practice between differing practitioners and institutions.

If intraprostatic seminal vesicle infiltration by tumor is to be indicative of stage T3b disease, then distinction from ejaculatory duct invasion becomes a critical issue. If not, then pathologists will have to accept the fact that there is no distinct cutoff between extra- and intraprostatic portions of the seminal vesicles. Amputation of the seminal vesicles close to their base would minimize this issue, but by no means eradicate it.

After consideration of the literature, the conference achieved consensus, voting that only invasion of cancer into the extraprostatic portion of the seminal vesicles should be considered to be seminal vesicle invasion (Table 1). It was suggested that when blocks of seminal vesicle are taken, care should be given to ensure that the seminal vesicles are not surrounded by prostatic tissue.

## Survey and Consensus Conference Results

The majority of respondents to the survey do not distinguish the type of seminal vesicle invasion, when present, although it should be straightforward to distinguish between the different forms of invasion if required. As mentioned above, there is only limited evidence that type of spread is of prognostic significance once other prognostic factors are accounted for. In view of this, there was consensus at the conference that such distinctions are not necessary in routine practice.

The rare situation was considered that if a tumor is present within endothelial-lined spaces in the muscular wall of the seminal vesicles, should this be categorized as pT3b? In the survey, 55% thought that vascular invasion was the equivalent of stromal invasion, whereas 45% did not. This situation was mirrored in the conference where the split was 56 and 44% (Table 1). Although the TNM classification advises that where there is doubt, the lower stage should be used, there is clearly no consensus at present in relation to examination of the prostate gland. Fortunately this situation occurs very infrequently, as vascular invasion by tumor in the prostate is itself uncommon.

## Lymph node metastasis

### Lymph Node Macroscopic Assessment

As radical prostatectomy is generally reserved for men at low risk of metastatic disease, the rate of lymph node involvement is generally low. Possible special techniques to examine the lymph nodes associated with surgical resection of the prostate include frozen sectioning of pelvic lymph nodes and sentinel lymph node sampling. Opinions as to the utility of frozen section diagnosis in assessment of pelvic lymph nodes at the time of radical prostatectomy have varied over the last 20 years. In 1986, Epstein *et al*<sup>35</sup> reviewed 310 patients and found that frozen sections detected 67% of positive lymph nodes that were grossly uninvolved by tumor, and 100% of the patients with grossly involved lymph nodes. In view of this detection of occult tumor deposits in macroscopically normal glands, the authors considered frozen section to be a valuable adjunct to radical prostatectomy. Young *et al*<sup>36</sup> in 1999 examined the cost and accuracy of frozen sections before radical prostatectomy and found a false-negative rate of 33%. These authors estimated the cost of metastatic cancer detection to be over \$10 000 and this, coupled with their demonstrated negative rate, led them to conclude that frozen section was not warranted as a routine procedure. Beissner *et al*<sup>37</sup> in 2002 found an even higher false-negative rate of 70% but, by stratifying patients into low, intermediate and high risk based on nomograms, the sensitivity of lymph node metastases was improved. They concluded that low-risk patients

(stage T2 or less, prostate specific-antigen (PSA) of  $\leq 10$  ng/ml and Gleason score of  $\leq 6$ ) gain no benefit from intraoperative frozen section, whereas the intermediate group (stage T2 or less and Gleason score 7 and/or PSA between 10.1 and 20 ng/ml) gained minimal benefit. The high-risk groups who have opted for surgery do gain benefit as they have a high risk of positive lymph nodes, and the detection of lymph node metastases would spare the patient the morbidity associated with an unnecessary radical prostatectomy. In parallel, the refinement of predictive tables for the risk of lymph node metastasis relative to biopsy Gleason score and presenting PSA has reduced the necessity for pre- or peri-operative nodal examination.<sup>38</sup> These findings suggest that the current evidence is that intraoperative frozen section is mainly helpful in high-risk patients to prevent unnecessary major surgery. Another intraoperative sampling technique, sentinel node surgery, has only recently been used in prostate pathology, and is usually used in a research setting.<sup>39</sup>

Staging of prostate cancer may be improved through the recovery of greater numbers of lymph nodes for examination purposes.<sup>40</sup> Xylene and other clearance techniques have been used by some to increase lymph node retrieval.<sup>41,42</sup> Fat clearance has been shown to increase lymph node harvest in other tumors such as carcinoma of the colon,<sup>43</sup> but the lymph nodes in colonic mesentery are well defined and lack the degree of fat infiltration seen in the pelvic nodes. Wawroschek *et al*<sup>42</sup> showed that by examining lymph nodes at several levels, combined with the use of immunohistochemistry, the node-positive rate in low-risk patients increased from 5 to 11%, but that there was a smaller increase, from 34 to 37%, in intermediate-risk patients. The cautionary note regarding the use of immunohistochemistry to detect micrometastasis is that we are uncertain of the prognostic significance of any tumor so detected, as there is a lack of studies in this area. Certainly, in some other comparable tumors, such as breast cancer, metastases  $< 2$  mm are classified separately to those of greater dimension. Considering the rarity of lymph node metastases in prostate cancer when compared with cancers from other organs, it appears unlikely that such stratification will be feasible in the foreseeable future.

### Survey and Consensus Conference Results

These conclusions were reflected in the survey results, where 22% reported never receiving an intraoperative frozen section, 57% received a frozen section in  $< 10\%$  of cases and only 21% of respondents received a frozen section with  $> 10\%$  of radical prostatectomy cases. From this it is clear that frozen section is used in a minority of cases, possibly being those of high risk where metastatic deposits to the lymph nodes are more likely. Only

2% of respondents reported ever receiving sentinel node samples.

Lymph node excision is not inevitably performed as part of a prostatectomy, and of the surveyed centers, 21% reported receiving lymph nodes with  $> 90\%$  of the specimens, 21% with 51–90% of specimens, 31% with 10–50% specimens and 26% with 1–10% of specimens. It was noted that one center never received lymph nodes as part of a radical prostatectomy procedure.

There was similar variability in how lymph nodes were submitted. Of the survey respondents, 2.5% reported receiving the lymph nodes, as left and right pelvic, in one container, 64% received them as left and right pelvic nodes in separate containers and 31% received specifically designated lymph node groups. There appears to be little uniformity among urologists as to how lymph nodes are submitted.

There was no consensus as to the optimal method for sampling the lymph nodes. In the survey, 27% reported that they sampled all the tissues submitted by the surgeon, 60% submitted only macroscopically identifiable nodal tissue and 8% processed only a sample of each lymph node identified. This was identified as a key area for the consensus conference, which also failed to reach consensus, although there was consensus that sampling of only a portion of each lymph node was inadequate. In the conference, 41% considered that it was necessary to submit all fat and nodal tissues, whereas 59% of participants considered the submission of purely nodal tissue sufficient.

### Lymph node microscopic assessment

There are little published data relating to the pathological examination of pelvic lymphadenectomies in patients undergoing radical prostatectomy. The number of lymph nodes obtained in a lymphadenectomy dissection varies widely among centers, which is a function of surgical technique as well as pathological practice. It was further recognized at the consensus conference that methods of nodal identification of lymph nodes by microscopy vary between pathologists. One study reported that a median of 16 nodes (range 5–40) could be detected for each patient, and that the rate of cancer detection increased with the number of nodes present, suggesting that a minimum of 13 nodes was required.<sup>40</sup> Such high yields, as reported in the survey, are not the norm and there was clear consensus that the number present should be recorded. This would be in concordance with lymphadenectomy assessment of other major cancers; however, it is recognized that counting of pelvic lymph nodes presents more of a challenge for pelvic lymph nodes than at many other sites, because of the large number showing replacement by adipose tissue.<sup>44</sup> It has also been suggested that lymph nodes in patients with significant prostate

cancers often show reactive change, making them easier to identify.<sup>41</sup>

Apart from assessment of the number of lymph nodes and their involvement by tumor, a number of studies have examined the characteristics of the deposits and their association with outcome. The diameter of the largest metastasis (Figure 1d) appears to be more predictive of cancer-specific survival than the number of positive nodes alone,<sup>45–47</sup> whereas the presence of extranodal extension has been shown not to be predictive on multivariate analysis.<sup>46</sup>

### Survey and Consensus Conference Results

Quantitation of the number of lymph nodes seen on microscopy was considered necessary information for a pathology report by the survey respondents, with 95% of pathologists reporting that they recorded this in the final report. However, it was noted that there is great variability in the number of nodes that are usually identified. Thus, 46% of respondents reported finding on average <5 lymph nodes per radical prostatectomy specimen, 40% found 5–10 lymph nodes, 8% found 11–15 lymph nodes whereas 3% found >15 lymph nodes.

In spite of this evidence, in the survey, 45% of respondents stated that they did not report on the size of the largest metastasis in lymph nodes, whereas 30% did report this. In all, 8% reported the size of the largest lymph node with a metastasis, and 17% reported both the size of the largest metastasis and the size of the largest involved lymph node. Of interest, 88% of the survey respondents reported extracapsular extension in spite of the fact that this was considered to be a feature of less prognostic significance. At the conference, there was a consensus of 81% that the diameter of the largest lymph node metastasis should be included in the final pathology report (Table 1).

### Disclosure/conflict of interest

The authors declare no conflict of interest.

### References

- 1 Cordon-Cardo C, Kotsianti A, Verbel DA, *et al*. Improved prediction of prostate cancer recurrence through systems pathology. *J Clin Invest* 2007;117:1876–1883.
- 2 Stephenson AJ, Scardino PT, Eastham JA, *et al*. Post-operative nomogram predicting the 10-year probability of prostate cancer recurrence after radical prostatectomy. *J Clin Oncol* 2005;23:7005–7012.
- 3 Da Pozzo LF, Cozzarini C, Briganti A, *et al*. Long-term follow-up of patients with prostate cancer and nodal metastases treated by pelvic lymphadenectomy and radical prostatectomy: the positive impact of adjuvant radiotherapy. *Eur Urol* 2009;55:1003–1011.
- 4 Walz J, Chun FK, Klein EA, *et al*. Nomogram predicting the probability of early recurrence after radical prostatectomy for prostate cancer. *J Urol* 2009;181:601–607.
- 5 Srigley JR. Key issues in handling and reporting radical prostatectomy specimens. *Arch Pathol Lab Med* 2006;130:303–317.
- 6 Epstein JI, Amin M, Boccon-Gibod L, *et al*. Prognostic factors and reporting of prostate carcinoma in radical prostatectomy and pelvic lymphadenectomy specimens. *Scand J Urol Nephrol Suppl* 2005;216:34–63.
- 7 Bostwick DG, Montironi R. Evaluating radical prostatectomy specimens: therapeutic and prognostic importance. *Virchows Arch* 1997;430:1–16.
- 8 Sakr WA, Grignon DJ. Prostate. Practice parameters, pathologic staging, and handling radical prostatectomy specimens. *Urol Clin North Am* 1999;2:453–463.
- 9 Montironi R, Mazzucchelli R, Kwast T. Morphological assessment of radical prostatectomy specimens. A protocol with clinical relevance. *Virchows Arch* 2003;442:211–217.
- 10 Egevad L, Algaba F, Berney DM, *et al*. Handling and reporting of radical prostatectomy specimens in Europe: a web-based survey by the European Network of Uropathology (ENUP). *Histopathology* 2008;53:333–339.
- 11 Egevad L, Srigley JR, Delahunt B. International Society of Urological Pathology (ISUP) consensus conference on handling and staging of radical prostatectomy specimens: rationale and organization. *Mod Pathol* 2010; in press.
- 12 Samaratunga H, Montironi R, True L, *et al*. International Society of Urological Pathologists (ISUP) consensus conference on handling and staging of radical prostatectomy specimens. Working group 1: specimen handling. *Mod Pathol* 2010; in press.
- 13 van der Kwast T, Amin MB, Billis A, *et al*. International Society of Urological Pathology (ISUP) consensus conference on handling and staging of prostatectomy specimens. Working group 2: T2 substaging and prostate cancer volume. *Mod Pathol* 2010; in press.
- 14 Magi-Galluzzi C, Evans A, Delahunt B, *et al*. International Society of Urological Pathology (ISUP) consensus conference on handling and staging of radical prostatectomy specimens. Working group 3: extraprostatic extension lymphovascular invasion and locally advanced disease. *Mod Pathol* 2010; in press.
- 15 Tan PH, Cheng L, Srigley JR, *et al*. International Society of Urological Pathology (ISUP): consensus conference on handling and staging of radical prostatectomy specimens. Working group 5: surgical margins. *Mod Pathol* 2010; in press.
- 16 Srigley JR, Humphrey PA, Amin MB, *et al*. Protocol for the examination of specimens from patients with carcinoma of the prostate gland. *Arch Pathol Lab Med* 2009;133:1568–1576.
- 17 Kench J, Clouston D, Delahunt B, *et al*. Royal college of pathologists of Australasia prostatecancer (Radical Prostatectomy) structured reporting protocol. 2010. 54 pp <http://www.rcpa.edu.au/Publications/StructuredReporting/CancerProtocols.htm>.
- 18 Epstein JI, Pizov G, Walsh PC. Correlation of pathologic findings with progression after radical retropubic prostatectomy. *Cancer* 1993;71:3582–3593.
- 19 Debras B, Guillonneau B, Bougaran J, *et al*. Prognostic significance of seminal vesicle invasion on the radical prostatectomy specimen. Rationale for seminal vesicle biopsies. *Eur Urol* 1998;33:271–277.

- 20 D'Amico AV, Whittington R, Malkowicz SB, *et al*. A multivariate analysis of clinical and pathological factors that predict for prostate specific antigen failure after radical prostatectomy for prostate cancer. *J Urol* 1995;154:131–138.
- 21 Tefilli MV, Gheiler EL, Tiguert R, *et al*. Prognostic indicators in patients with seminal vesicle involvement following radical prostatectomy for clinically localized prostate cancer. *J Urol* 1998;160:802–806.
- 22 Potter SR, Epstein JI, Partin AW. Seminal vesicle invasion by prostate cancer: prognostic significance and therapeutic implications. *Rev Urol* 2000;2:190–195.
- 23 van den Ouden D, Hop WC, Kranse R, *et al*. Tumour control according to pathological variables in patients treated by radical prostatectomy for clinically localized carcinoma of the prostate. *Br J Urol* 1997;79:203–211.
- 24 Catalona WJ, Smith DS. 5-year tumor recurrence rates after anatomical radical retropubic prostatectomy for prostate cancer. *J Urol* 1994;152:1837–1842.
- 25 Trapasso JG, deKernion JB, Smith RB, *et al*. The incidence and significance of detectable levels of serum prostate specific antigen after radical prostatectomy. *J Urol* 1994;152:1821–1825.
- 26 Epstein JI, Partin AW, Sauvageot J, *et al*. Prediction of progression following radical prostatectomy. A multivariate analysis of 721 men with long-term follow-up. *Am J Surg Pathol* 1996;20:286–292.
- 27 Ohori M, Wheeler TM, Kattan MW, *et al*. Prognostic significance of positive surgical margins in radical prostatectomy specimens. *J Urol* 1995;154:1818–1824.
- 28 Ohori M, Scardino PT, Lapin SL, *et al*. The mechanisms and prognostic significance of seminal vesicle involvement by prostate cancer. *Am J Surg Pathol* 1993;17:1252–1261.
- 29 Jewett HJ, Eggleston JC, Yawn DH. Radical prostatectomy in the management of carcinoma of the prostate: probable causes of some therapeutic failures. *J Urol* 1972;107:1034–1040.
- 30 Soh S, Arakawa A, Suyama K, *et al*. The prognosis of patients with seminal vesicle involvement depends upon the level of extraprostatic extension. *J Urol* 1998;159:296A.
- 31 Wheeler TM. Anatomic considerations in carcinoma of the prostate. *Urol Clin North Am* 1989;16:623–634.
- 32 Villers AA, McNeal JE, Redwine EA, *et al*. Pathogenesis and biological significance of seminal vesicle invasion in prostatic adenocarcinoma. *J Urol* 1990;143:1183–1187.
- 33 Epstein JI, Partin AW, Potter SR, *et al*. Adenocarcinoma of the prostate invading the seminal vesicle: prognostic stratification based on pathologic parameters. *Urology* 2000;56:283–288.
- 34 Yamamoto S, Kawakami S, Yonese J, *et al*. Prognostic significance of cancer volume involving seminal vesicles in patients with pT3bpN0 prostate cancer. *Urology* 2008;72:1224–1228.
- 35 Epstein JI, Oesterling JE, Eggleston JC, *et al*. Frozen section detection of lymph node metastases in prostatic carcinoma: accuracy in grossly uninvolved pelvic lymphadenectomy specimens. *J Urol* 1986;136:1234–1237.
- 36 Young MP, Kirby RS, O'Donoghue EP, *et al*. Accuracy and cost of intraoperative lymph node frozen sections at radical prostatectomy. *J Clin Pathol* 1999;52:925–927.
- 37 Beissner RS, Stricker JB, Speights VO, *et al*. Frozen section diagnosis of metastatic prostate adenocarcinoma in pelvic lymphadenectomy compared with nomogram prediction of metastasis. *Urology* 2002;59:721–725.
- 38 Partin AW, Mangold LA, Lamm DM, *et al*. Contemporary update of prostate cancer staging nomograms (Partin Tables) for the new millennium. *Urology* 2001;58:843–848.
- 39 Holl G, Dorn R, Wengenmair H, *et al*. Validation of sentinel lymph node dissection in prostate cancer: experience in more than 2000 patients. *Eur J Nucl Med Mol Imaging* 2009;36:1377–1382.
- 40 Barth PJ, Gerharz EW, Ramaswamy A, *et al*. The influence of lymph node counts on the detection of pelvic lymph node metastasis in prostate cancer. *Pathol Res Pract* 1999;195:633–636.
- 41 Weingartner K, Ramaswamy A, Bittinger A, *et al*. Anatomical basis for pelvic lymphadenectomy in prostate cancer: results of an autopsy study and implications for the clinic. *J Urol* 1996;156:1969–1971.
- 42 Wawroschek F, Wagner T, Hamm M, *et al*. The influence of serial sections, immunohistochemistry, and extension of pelvic lymph node dissection on the lymph node status in clinically localized prostate cancer. *Eur Urol* 2003;43:132–136.
- 43 Scott KW, Grace RH. Detection of lymph node metastases in colorectal carcinoma before and after fat clearance. *Br J Surg* 1989;76:1165–1167.
- 44 Winstanley AM, Sandison A, Bott SR, *et al*. Incidental findings in pelvic lymph nodes at radical prostatectomy. *J Clin Pathol* 2002;55:623–626.
- 45 Cheng L, Bergstralh EJ, Chevillie JC, *et al*. Cancer volume of lymph node metastasis predicts progression in prostate cancer. *Am J Surg Pathol* 1998;22:1491–1500.
- 46 Cheng L, Pisansky TM, Ramnani DM, *et al*. Extranodal extension in lymph node-positive prostate cancer. *Mod Pathol* 2000;13:113–138.
- 47 Boormans JL, Wildhagen MF, Bangma CH, *et al*. Histopathological characteristics of lymph node metastases predict cancer-specific survival in node-positive prostate cancer. *BJU Int* 2008;102:1589–1593.

## Appendix

### The members of the ISUP Prostate Cancer Group are:

Adebowale Adeniran, Hikmat Al-Ahmadie, Ferran Algaba, Robert Allan, Mahul Amin, Marc Barry,

Sheldon Bastacky, Dilek Baydar, Louis Bégin, Dan Berney, Athanase Billis, Liliane Boccon-Gibod, David Bostwick, Maria Brito, Tucker Burks, Christer Busch, Philippe Camparo, Liang Cheng, Cynthia Cohen, Milton Datta, Laurence de Leval, Brett Delahunt, Warick Delprado, Lars Egevad, Jonathan Epstein, Andrew Evans, Sara Falzarano, Samson Fine, Eddie Fridman, Bungo Furusato, Masoud Ganji, Lisa Glantz,

Anuradha Gopalan, David Grignon, Rainer Grobholz, Charles Guo, Rekha Gupta, Bora Gurel, Seife Hailemariam, Ardeshir Hakam, Omar Hameed, Donna Hansel, R-Peter Henke, Mehsati Herawi, Michelle Hirsch, Jiaoti Huang, Wei Huang, Christina Hulsbergen van de Kaa, Peter Humphrey, Kenneth Iczkowski, Edward Jones, Michael Jones, Laura Jufe, James Kench, Hyun-Jung Kim, Peter Kragel, Glen Kristiansen, Katia Ramos Moreira Leite, Claudio Daniel Lewin, Josep Lloreta, Antonio Lopez-Beltran, Scott Lucia, Dani el Luthringer, Cristina Magi-Galluzzi, Peter McCue, Teresa McHale, Jesse McKenney, Maria Merino, Rodolfo Montironi, Gabriella Nesi, George Netto, Esther Oliva,

Pedro Oliveira, Adeboye Osunkoya, Gladell Paner, Anil Parwani, Maria Picken, Galina Pizov, Andrew Renshaw, Jae Ro, Stephen Rohan, Ruben Ronchetti, Mark Rubin, Hemamali Samaratunga, Anna Sankila, Alan Schned, Isabell Sesterhenn, Ahmed Shabaik, Rajal Shah, Jonathan Shanks, Steven Shen, Jungweon Shim, Taizo Shiraishi, VO Speights, Jr, John Srigley, Ming-Tse Sung, Sueli Suzigan, Hiroyuki Takahashi, Puay Hoon Tan, Bernard Tetu, Satish Tickoo, John Tomaszewski, Patricia Troncoso, Kiril Trpkov, Lawrence True, Toyonori Tsuzuki, Jennifer Turner, Theo van der Kwast, Mark Weiss, Thomas Wheeler, Kirk Wojno, Keith Volmar, Chin-Lee Wu, Jorge Yao, Asli Yilmaz, Jim Zhai.